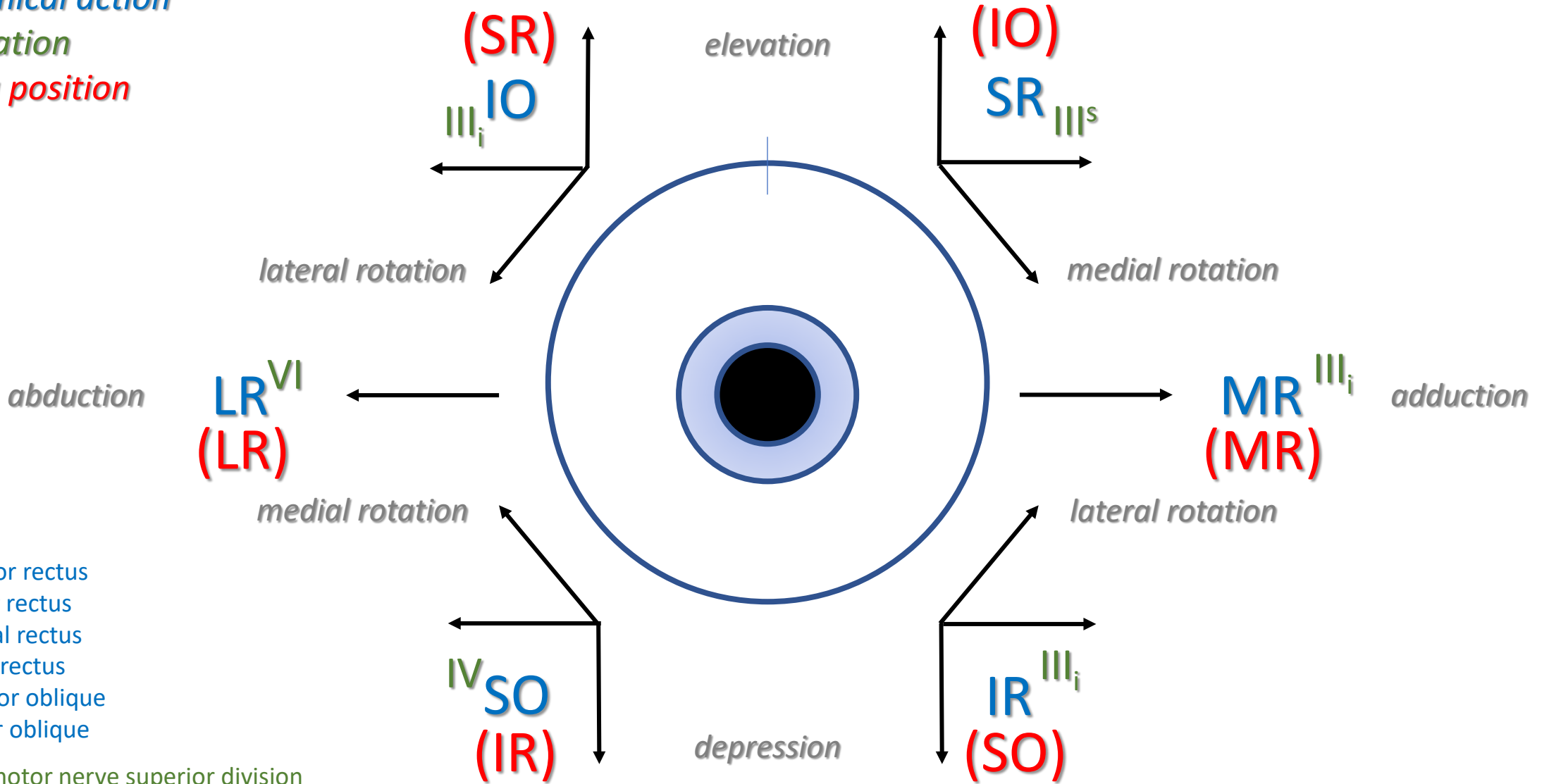


# R eye

*anatomical action*

*innervation*

*testing position*



SR superior rectus

IR inferior rectus

MR medial rectus

LR lateral rectus

SO superior oblique

IO inferior oblique

$III^s$  oculomotor nerve superior division

$III_i$  oculomotor nerve inferior division

IV trochlear nerve

VI abducens nerve